

Seeing The Difference

Two ophthalmologists share how Topcon's DRI OCT Triton makes a difference in their clinics.

By Julian Upton

Topcon Healthcare (Tokyo, Japan), a market-leader in the field of Optical Coherence Tomography (OCT) instrumentation, has consistently developed and innovated spectral domain (SD) and swept-source (SS) OCT technologies.

DRI OCT Triton represents the third-generation of OCT technology and combines deep scanning capabilities with the ability to penetrate media opacities with ultra-fast SS imaging

(100,000 A-scans/s). Triton has the ability to capture comprehensive retinal and choroidal data in a single scan and produces more images to enhance the clinical decision-making process. In addition, Triton uses stereo photography to capture true-color fundus images in 3D, and thanks to its auto-mosaic panorama function, Triton provides wide coverage of the retina into the periphery (which includes most of the fundus).

contact lens and local treatment with topical antibiotic 4 times daily for 5 days, steroid (Prednisolone acetate) eye drops 6 times daily and Bromfenac eye drops 2 times daily.

One week after uncomplicated DMEK surgery, a slight inferior graft detachment was observed. The topical treatment

of steroid eye drops 6 times daily with monthly tapering and Bromfenac 2 times daily were continued.

Corneal imaging was performed at the two-week postoperative follow-up using anterior segment Triton OCT (Topcon, Japan) (Figures 1 & 2). The transplant detachment can be detected

using the line scan and localized to the cornea's inferior part. Due to Triton's swept-source technology, the corneal and scleral tissue were easily penetrated, allowing for detailed visualization of the anterior chamber structures, including the transplant detachment, with a high degree of clarity.

CASE STUDY ONE:

DMEK Graft Detachment

Oliver Findl, Chief of the Department of Ophthalmology at the Vienna Hanusch Hospital.

A 79-year-old Caucasian male presented to our cornea department with decreased visual acuity in the left eye, persisting after uncomplicated cataract surgery of both eyes.

Two months prior to presentation, cataract surgery had been performed in our department. At the time, the preoperative examination revealed a clear cornea, deep anterior chamber with nuclear cataract and normal retinal examination for both eyes.

The IOL power calculation was performed using IOLMaster 700 (Carl Zeiss Meditec,

Dublin, California, USA): OD: keratometry 8.27@88/ 7.66@178, ACD: 2.77, AL: 22.46 mm. OS: keratometry 7.96@ 77/ 7.80 @ 167, ACD: 2.78, AL: 23.38 mm. A 24.00 D / 4.00 cyl monofocal toric lens (Zeiss AT Torbi 709) was implanted at 178 degrees in the right eye and a standard monofocal intraocular lens was implanted in the left eye.

At examination (two months after cataract surgery), the patient's best corrected visual acuity was 0.8 in the right eye and hand motion in the left eye. Autorefractometry was: -0.25 -0.50 X 19 (right eye) and -2.50 -2.50 X 148 (left eye). The slit-lamp examination revealed a clear cornea, with deep anterior chamber and pseudophakia for the right eye and corneal oedema, Descemet folds, and pseudophakia for the left eye. No other ocular structures were visible due to the corneal oedema in the left eye. The central corneal thickness

(CCT) of the left eye was 760 µm.

Ropasudil (GLANATEC® ophthalmic solution 0.4%) eye drops 3 times daily and Omni-Sorb® NaCl 5% eye drops 3 times daily were started in the left eye, with a planned follow-up examinations at 2 weeks (after first presentation to our department), 2 months, and 3 months.

At the two-week appointment, a slight improvement of the left eye cornea was observed, with the oedema (CCT 650 µm) now concentrated within the 5 mm central area of the cornea. Treatment with Ropasudil and NaCl drops were continued at the same intervals.

At the two months follow-up, the best corrected visual acuity of the right eye was 0.63 and 0.1 for the left eye. The left eye CCT was 584 µm and the slit-lamp examination revealed central corneal oedema, deep anterior chamber, pseudophakia and a normal retinal examination. Ropasudil eye drops 3 times daily were continued, with a follow-up scheduled for one month.

Three months post-cataract surgery, the patient presented with increased corneal oedema inferiorly (CCT 650 µm) in the left eye despite the use of Ropasudil eye drops, thus a Descemet Membrane Endothelial Keratoplasty (DMEK) surgery was planned.

DMEK surgery of the left eye was performed a month later under local anaesthesia. At the conclusion of the surgery, the patient received a bandage

CASE STUDY TWO:

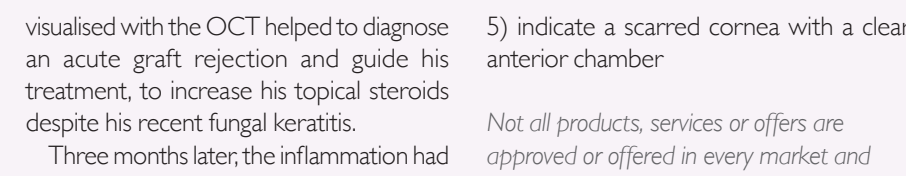
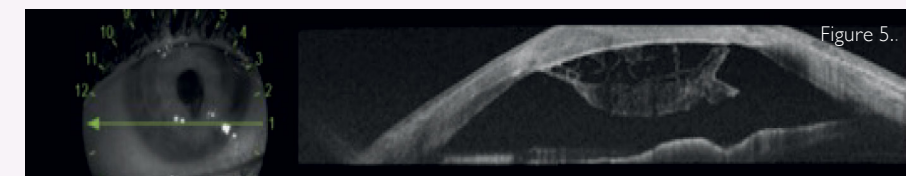
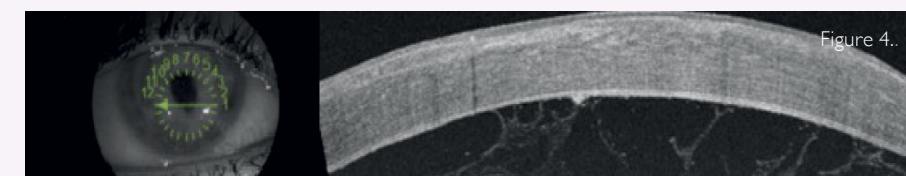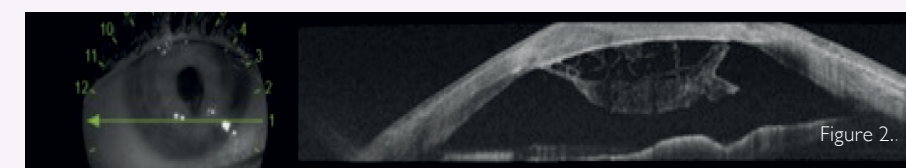
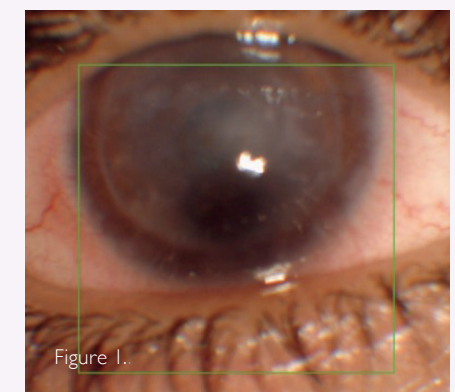
Fungal Keratitis and graft rejection

Mr Mark Lane is an ST7 Ophthalmology trainee in the West Midlands Deanery. He is specializing in the cornea and anterior segment, and is due to start a post-training fellowship in Moorfields in August 2023.

A 19-year-old male patient presented to the specialist corneal clinic for ongoing therapy. The patient has a history of severe eczema affecting the face and periorcular region that required systemic immunosuppression. Due to his associated ocular surface disease, he had previously suffered from bilateral corneal perforations requiring emergency management and a tectonic corneal graft to the right eye. The patient initially regained vision in the postoperative period. He later developed fungal keratitis in the tectonic corneal graft and was treated with topical voriconazole, natamycin and intrastromal amphotericin B and levofloxacin drops.

On clinical examination, the patient's vision was hand movements, and he appeared to have a chronic corneal graft failure. The anterior color photograph indicates a generalized corneal haze and oedema with no evidence of recurrence of the fungal infiltrate. (Fig. 1)

The AS OCT (Fig. 2 and 3) (Topcon DRI OCT Triton, Tokyo, Japan) demonstrated the presence of dense fibrin plaque in the anterior segment that was adherent to the endothelium. The extensive inflammation



visualised with the OCT helped to diagnose an acute graft rejection and guide his treatment, to increase his topical steroids despite his recent fungal keratitis.

Three months later, the inflammation had improved, and the patient was no longer in acute rejection. The anterior segment OCT and colour photograph (Fig. 4 and

5) indicate a scarred cornea with a clear anterior chamber

Not all products, services or offers are approved or offered in every market and products vary from one country to another. Contact your local distributor for country-specific information.

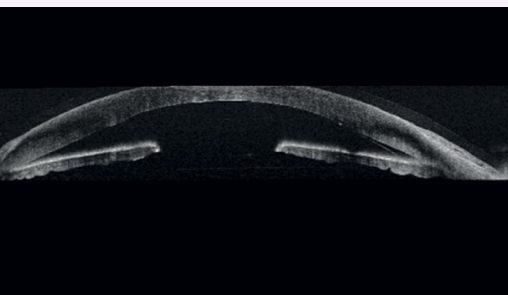


Figure 1. Line Anterior segment OCT (Triton) two week after DMEK surgery, inferior detachment of the transplant can be seen

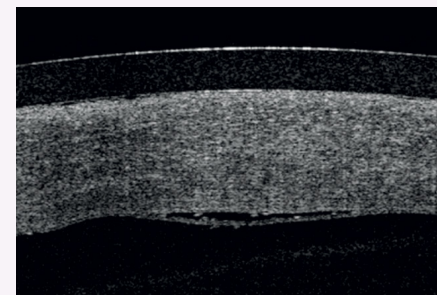


Figure 2. Anterior segment OCT 3.0x3.0mm (Triton) two weeks post-DMEK surgery transplant folds can be seen.